



PATIENT

Frank Steinmetz

SPECIES

Canine

BREED

Cocker Spaniel

SEX

Male Neutered

AGE

12 years

WEIGHT

38.5lbs

INTERPRETED BY

Maggie Machen
Lamy, DVM, DACVIM
(Cardiology)

IMAGING PERFORMED BY

Jenna Walsh, CVT

HOSPITAL NAME

VCA Delta Oaks
Animal Hospital

REFERRING VET

Dr. Lahm

INVOICE

25246

DATE

7/11/22

PRESENTING CLINICAL SIGNS

History: Grade 3/6 heart murmur. Assess prior to anesthesia.

ELECTROCARDIOGRAPHIC FINDINGS *Note: Single lead ECGs are evaluated as a rhythm strip.

Morphology/MEA cannot be definitively commented on.

A single lead ECG is available; 50mm/s, 10mm/mV. The average heart rate is 75bpm (range 65-90bpm). The rhythm is sinus in origin, with a p for every QRS complex and vice versa. The P and QRS morphologies are positive. No ectopic beats, pauses or dysrhythmias observed.

ECG diagnosis: Sinus bradycardia with respiratory variation.

ECHOCARDIOGRAM FINDINGS

2D, m-mode, color flow and doppler imaging is available. Diffuse thickening of mitral valve leaflets (anterior>posterior) with no prolapse into the left atrial lumen. Moderate eccentric mitral regurgitation with moderate left atrial dilation. Normal MR velocity. Mildly increased LV diameter with hyperdynamic myocardial function. The tricuspid valve appears mildly thickened with moderate tricuspid regurgitation. Velocity consistent with early pulmonary hypertension. Normal right atrial and ventricular diameter. The pulmonic and aortic valves are normal in morphology and mobility. Normal pulmonic and aortic outflow velocities. No aortic or pulmonic insufficiency. No pericardial or pleural effusion noted. No cardiac tumors observed.

CARDIAC CHART

CANINE CARDIAC PARAMETERS	MR VMAX (m/s)	TR VMAX (m/s)	LA/AO (Boon method)	LA/AO (Heart Base; Swe)	FS (%)	EF (%)	EPSS (cm)
NORMAL PARAMETER	4.5-5.5	<2.7	1.3	<1.6	28-40	40-100	<0.6
PATIENT	6.3	3.1	1.8	1.8	34	64	0.4
CANINE CARDIAC PARAMETERS	HR (BPM)	AV VMAX (m/s)	PV MAX (m/s)	BODY WEIGHT (kg)	LA 2D short axis Base view (cm)	LVIDd Avg; 2D and m-mode short axis (cm)	LVIDs Avg; 2D and m-mode short axis (cm)
NORMAL PARAMETER	50-100	0.7-1.7	0.7-1.6	BELOW	BELOW	BELOW	BELOW
PATIENT	100	NM	1.2	17.5	3.1	3.5	2.3
*Normal chamber parameters expressed as a mean value (SD)				3	1.27 (5.3)	2.46 (2.46)	1.36 (5.5)
BODY WEIGHT DEPENDENT PARAMETERS				5	1.40 (4.5)	2.74 (5.2)	1.60 (4.7)
				10	1.50 (3.8)	3.27 (3.5)	2.06 (3.1)
				15	1.83 (2.0)	3.71 (2.4)	2.43 (2.1)
				20	2.02 (1.9)	4.14 (2.2)	2.80 (2.0)
				25	2.18 (2.4)	4.48 (2.9)	3.10 (2.5)
				30	2.33 (3.3)	4.83 (3.9)	3.39 (3.4)
				35	2.48 (4.3)	5.17 (5.0)	3.69 (4.5)
				40	2.62 (5.2)	5.48 (6.1)	3.96 (5.4)
				50	2.88 (7.1)	6.07 (8.3)	4.46 (7.4)

Adapted from June Boon, Veterinary Echocardiography, 1998
 Rishniw M and Hollis NE, J Vet Intern Med 2000; 14:429-435
 Hansson et al, Vet Rad and Ultrasound 2002
 Bonagura et al. Echocardiography: principles of interpretation, Vet Clin North Am 15:1177, 1995



PATIENT

Frank Steinmetz

SPECIES

Canine

BREED

Cocker Spaniel

SEX

Male Neutered

AGE

12 years

WEIGHT

38.5lbs

INTERPRETED BY

Maggie Machen
Lamy, DVM, DACVIM
(Cardiology)

IMAGING PERFORMED BY

Jenna Walsh, CVT

HOSPITAL NAME

VCA Delta Oaks
Animal Hospital

REFERRING VET

Dr. Lahm

INVOICE

25246

DATE

7/11/22

INTERPRETATION OF THE FINDINGS & FURTHER RECOMMENDATIONS

Chronic degenerative valve disease causing moderate mitral and tricuspid regurgitation. Moderate left atrial enlargement indicates there is relatively low risk for imminent complication, however risk for progression to spontaneous congestive heart failure in the future is elevated. Early pulmonary hypertension is noted, which should be monitored going forward. No additional issues are identified.

The ECG shows a sinus bradycardia with a low resting heart rate. If this is independent of sedation, highly recommend an Atropine challenge be performed prior to induction to ensure normal response prior to proceeding. If the response is lackluster, the procedure should be aborted and a holter monitor considered.

Given the risk for progression and results of the EPIC trial, Pimobendan is indicated in this patient as below. Assessment of progression in the future will help predict long term outcome, however prognosis is guarded at this stage (B2).

Omega fatty acid supplementation and mild salt restriction may also be of some long-term benefit. Monitor for development of a progressive cough, labored breathing, exercise intolerance or collapse episodes.

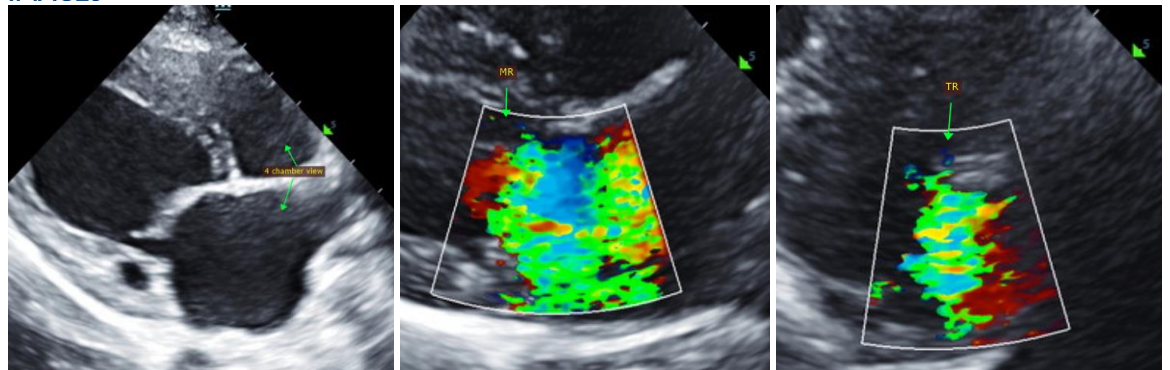
Once on the medication for 3-5 days, anesthetic risk is considered mildly elevated pending a normal atropine challenge. Cardiac protective drug choices (opioid/benzodiazepine premedication, Propofol or alfaxalone induction, iso or sevo gas) are recommended. Monitor for arrhythmias, hypotension, and hypoxia both intra and post-operatively and intervene as necessary. Judicious IV fluid rates are recommended to avoid fluid overload.

PLAN

An atropine challenge immediately prior to anesthesia is recommended: Give 0.04mg/kg IV or IM and assess response. Baseline BP recommended. Institute heart muscle support Pimobendan 0.25-0.3mg/kg PO q12h.

Recommend monitor for progression with a recheck echocardiogram in 6 months, sooner if any development of clinical signs.

IMAGES





PATIENT

Frank Steinmetz

SPECIES

Canine

BREED

Cocker Spaniel

SEX

Male Neutered

AGE

12 years

WEIGHT

38.5lbs

INTERPRETED BY

Maggie Machen
Lamy, DVM, DACVIM
(Cardiology)

IMAGING PERFORMED BY

Jenna Walsh, CVT

HOSPITAL NAME

VCA Delta Oaks
Animal Hospital

REFERRING VET

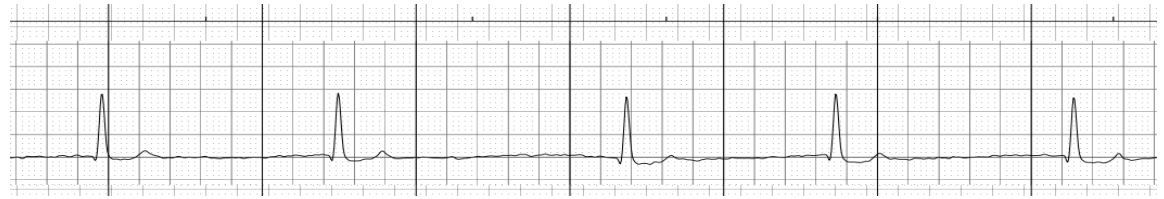Dr. Lahm

INVOICE

25246

DATE

7/11/22



The information and recommendations provided are based on the images presented by the referring veterinarian. No evaluation can be communicated regarding pathology that was not visible in the image/video clips provided.

Thank you for this referral. This report was generated using transcription software, and minor dictation errors may be present. If the clinical or image interpretation does not parallel your findings or if I can be of any further assistance, please contact me.

Maggie Machen Lamy, DVM
Diplomate of the American College of Veterinary Internal Medicine (Cardiology)
info@sonopath.com